

# UNA SALUD – ONE HEALTH



## Newsletter

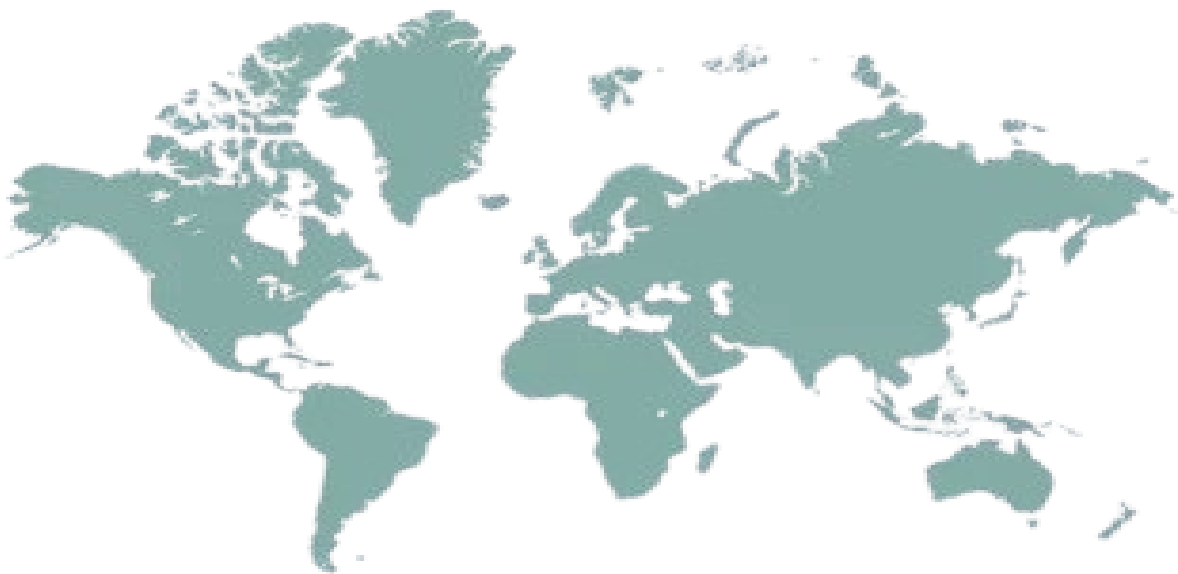# 7 – April 2025



# TABLE OF CONTENTS

## PROLOGUE

1. THE EARLY PERFORMANCE OF HYPERBARIC OXYGEN THERAPY IN THE TREATMENT OF BOTHROPS SNAKEBITE IN A CHIHUAHUA DOG – REPORT CASE
2. HIPERBARIC OXIGEN THERAPY OF BONE NON-UNION ASSOCIATED WITH POSSIBLE OSTEOMYELITIS
3. CLINICAL CASE OF NERVOUS CANINE DISTEMPER TREATED WITH PHYSIATRY AND OZONE THERAPY
4. TERMOGRAPHY IN ANIMAL MEDICINE IN A NUTSHELL
5. THE REGENERATION DILEMMA: ADVANCES AND CHALLENGES IN VETERINARY CELL THERAPY



**One Healt**



Grupo Andes – Investigación y Desarrollo en Medicina Regenerativa Veterinaria (C) Copyright (2025) Todos los Derechos Reservados

## PROLOGUE


**A**pril finds us once again sharing the advances, activities, and reflections emerging within the ANDES Group, an organization committed to research, training, and consulting in the field of veterinary regenerative medicine and orthobiophisiatry. Our daily work is guided by a clear objective: to promote the development of these disciplines through ongoing training and the generation of applied scientific knowledge.

In this newsletter, we reaffirm our mission to contribute to the advancement of regenerative medicine and veterinary orthobiophisiatry, promoting innovative solutions that emerge from scientific and technological work, with a comprehensive and collaborative approach. Through our activities, we seek to be a bridge between science and clinical practice, and to support professionals in their growth and development.

Likewise, we remain firm in our vision of positioning ourselves as a national and international benchmark in these areas, with a positive impact on both the scientific community and veterinary clinics.

In line with the principles of One Health, we emphasize the importance of understanding veterinary medicine as an essential part of holistic health. Today more than ever, the connection between animal, human, and environmental health invites us to strengthen interdisciplinary dialogue among health professions. In this sense, ANDES Group promotes a collaborative approach, aware that current health challenges require joint, ethical, and evidence-based responses.

We invite you to explore this newsletter as a space for meeting, updating, and projecting toward a future where science, technology, and cooperation continue to be the foundations of progress in regenerative medicine and veterinary orthobiophisiatry.



***Dra. Ana María Pedernera***

*Researcher at IntegraVet*

*Center for Physical Therapy and Regenerative Medicine*

*Academic Coordinator, Andes Group*



# 1. The Early Performance Of Hyperbaric Oxygen Therapy In The Treatment Of Bothrops Snakebite In A Chihuahua Dog – Report Case

La realización temprana de oxigenoterapia hiperbárica en el tratamiento de mordedura de serpiente botrops en un perro Chihuahua - Reporte de caso

A atuação precoce da oxigenoterapia hiperbárica no tratamento de acidente ofídico com botrops em um cão Chihuahua- Relato de Caso



**Marcelo Fialho Mazzi**<sup>1\*</sup>. Juliano Veiga de Oliveira<sup>2</sup>

<sup>1</sup> Médico Veterinário Hiperbarista CRMV-SP 8753, ORCID 0000-0003-4168-2645 iD, MAZZIVET- Medicina Veterinária Avançada. São João da Boa Vista- SP, Brasil.

<sup>2</sup> Médico Veterinário CRMV-DF 1367. Brasília-DF, Brasil.

\*corresponding author: e-mail: [mazzivet@hotmail.com](mailto:mazzivet@hotmail.com)

**RESUMEN.** Las serpientes venenosas que con mayor frecuencia afectan a los animales domésticos en Brasil son del género Bothrops, debido a su curioso comportamiento, el perro es más susceptible a estos accidentes. El pronóstico para los animales envenenados puede ser variable. Este artículo reporta el diagnóstico y abordaje terapéutico en el caso de una mordedura de serpiente Botrops, asociado al tratamiento convencional, oxigenoterapia hiperbárica temprana, en un perro adulto, Chihuahua, con un peso de 3 kg. Se administraron sueros polivalentes, ceftriaxona, prednisolona, tramadol y sesiones de oxigenoterapia hiperbárica. Después de la tercera sesión hiperbárica el edema remitió completamente, sin necrosis por picadura de jararaca. Se concluyó que el uso temprano de la oxigenoterapia hiperbárica, asociada al tratamiento convencional en este informe, demostró ser una herramienta diferencial en el tratamiento de emergencia de las mordeduras de serpiente, superando las expectativas, justificando su indicación primaria en tales situaciones.

**Palabras clave:** mordedura de serpiente, necrosis, oxígeno, tratamiento



**RESUMO.** As serpentes peçonhentas que com maior frequência acometem animais domésticos no Brasil são do gênero *Bothrops*, devido ao seu comportamento curioso, o cão, está mais susceptível a estes acidentes. O prognóstico dos animais envenenados pode ser variável. O presente artigo relata o diagnóstico e a conduta terapêutica em caso de picada de serpente *Bothrops*, associando-se ao tratamento convênacional, a oxigenoterapia hiperbárica de forma precoce, em uma cadela, Chiuaua, adulta, com 3Kg. Foi realizado soro polivalente, ceftriaxona, prednisolona, tramadol e sessões de oxigenoterapia hiperbárica. Após a realização da terceira sessão hiperbárica, averigou-se a total remissão do edema, não ocorrendo necrose decorrente da picada de jararaca. Concluiu-se que o uso do oxigenoterapia hiperbárica de forma precoce, associada ao tratamento convencional neste relato, demonstrou ser ferramenta diferencial no tratamento emergencial de acidentes ofídicos, suplantando as expectativas, justificando sua primária indicação em tais situações.

**Palavras chave:** ofidismo, necrose, oxigênio, tratamento

**ABSTRACT.** The venomous snakes that most frequently affect domestic animals in Brazil are of the *Bothrops* genus, due to their curious behavior, the dog, is more susceptible to these accidents. The prognosis of poisoned animals can vary. The present article reports the diagnosis and the therapeutic conduct in case of *Bothrops* snake bite, associated with the conventional treatment in an early way, hyperbaric oxygen therapy, in a dog, female, Chiuaua, adult, with 3Kg. Polyvalent serum, ceftriaxone, prednisolone, tramadol

and hyperbaric oxygen therapy treatments were performed. After the third hyperbaric treatment, the complete remission of the edema was verified, with no necrosis resulting from the bite of the jararaca. It was concluded that the early use of hyperbaric oxygen therapy associated with conventional treatment in this report, proved to be a differential tool in the emergency treatment of snakebites, surpassing expectations, justifying its primary indication in such situations.

**Keywords:** snakebite, necrosis, oxygen, treatment



## INTRODUCTION

FUNASA, (2001), defines venomous animals as individuals that have venom-producing glands, associated with specialized mechanisms for inoculating the same, and/or toxic substances, exemplified by spiders, scorpions, caterpillars, bees and snakes.

CHIPPAUX, (1998), lists that there are around 3,000 cataloged snake species in the world, with 10 to 14% of this total considered venomous or poisonous. In Brazil, FERNANDES et al., (2008), adds that approximately 256 species have been recorded, 70 of which are considered venomous and divided into four groups.

BRASIL, (2005), details that in humans in Brazil, snakes of the Bothrops genus are responsible for 87.5% of all snakebites reported in the country, followed by crotalic (9.2%), lachetic (2.7%) and elapid (0.6%), with small variations according to the region and geographic distribution of the snakes.

BARNI et al., (2012), point out that in veterinary medicine, statistics regarding the occurrence of snakebite accidents are not reliable because there is no obligation to report them; despite this, BICUDO, (2003), states that companion

animals are frequent victims of poisoning by venomous attacks.

SAKATE, (2002), attributes the high susceptibility of dogs to such accidents to the inherent curious behavior of the species, and his thesis is reinforced by PUZZI et al., (2008), when he attributes the snout as the anatomical region most affected in snake attacks on domestic animals.

GOMES, (2008), describes that it is rare to accurately identify the species of snake involved in these occurrences, initially because the owner is not present, and when eventually captured and taken to the veterinarian, the snakes are dead or often mutilated, making their recognition difficult.

MELGAREJO, (2009), details that the Bothrops genus comprises more than 60 species of snakes, distributed from northern Mexico to southern Argentina, but several species were redistributed into seven other genera; in Brazil these snakes have different designs, colors and sizes, having in common the loreal pit, the smooth end of the tail, being solenoglyphous, ovoviviparous and with very aggressive behavior, and can be found throughout the national territory.



FRANÇA and MÁLAQUE, (2009), report that Bothrops venom has more than 20 different components, of which more than 90% of its dry weight is proteins, including enzymes, non-enzymatic toxins and non-toxic proteins, also presenting carbohydrates, lipids, metals, biogenic amines, nucleotides and free amino acids, ROCHA and FURTADO, (2005), add that there are factors that will directly interfere in this composition, such as the age of the snake, its geographic location, as well as individual characteristics of the aggressor.

BLANCO and MELO, (2014), divide the pathophysiological activities of this type of venom into four groups, namely, proteolytic, coagulant/anticoagulant, vasculotoxic and nephrotoxic.

MELO, et al., (2004), confer proteolytic activity, also known as necrotic or acute inflammatory, being caused by several components, including high concentrations of proteolytic enzymes and by indirect action in the induction or release of autacoids such as bradykinin, prostaglandins, leukotrienes and prostacyclins.

BLANCO and MELO, (2014), confer the potentiation of the acute local inflammatory process, the coagulant activity of the venom, leading to the

formation of thrombi in the microvasculature, which are responsible for tissue hypoxia and consequent worsening of edema and tissue necrosis.

SAKATE (2008), attributes the rapid absorption and dispersion of the venom between animal tissues to the presence of the enzyme hyaluronidase in its primary composition.

BLANCO and MELO, (2014), attribute its coagulant activity to several compounds such as the activation of blood coagulation factors (fibrinogen, prothrombin and factor X), occurring isolatedly or simultaneously, converting fibrinogen into unstable fibrin, resulting in an increase in coagulation time or making it incoagulable.

FERREIRA JÚNIOR and BARRAVIERA, (2004), describe the formation of microclots, triggering a case of disseminated intravascular coagulation (DIC) in the affected individual.

DALLEGRAVE and SEBBEN, (2008), attribute its systemic vasculotoxic activity to metalloproteinases, a group of enzymes that contain zinc in their structure, called hemorrhagins, which disrupt vascular integrity by degrading components of the



extracellular matrix and their nephrotoxic effect, resulting from the direct action of the venom on the renal tubules and vascular endothelium, progressing to acute

renal failure as a predictable sequela for the patient.

LUCIANO et al., (2009), classify the severity of accidents with Bothrops, based on the symptoms observed (Table 1).

**Table 1. Classification of botropic accidents according to severity**

<b>Manifestations</b>	<b>Mild</b>	<b>Moderate</b>	<b>Severe</b>
Local: Pain, edema, ecchymosis	Absent or discreet	Evident	Intense
Systemic: Severe bleeding, shock and anuria	Absent	Absent	Present
Coagulation Time - TC	Normal or changed	Normal or changed	Normal or changed

**Source:** Adapted from Luciano et al., (2009).

SILVA et al., (2016), characterize the majority of accidents caused by snakes of the Bothrops genus in domestic animals as having clinical signs associated with local edema, bruising, pain, prostration and hemorrhage at the site of the bite.

BERROCAL et al., (1998) consider that the clinical condition will depend on the animal's sensitivity to the venom, the amount of venom injected, the time elapsed since the accident and the affected area.

MENDEZ; RIET-CORREA, (1995), add that in the case of a regional sting to the snout, the reaction may cause severe edema, affecting the lower jaw, neck and thoracic region,

causing obstruction of the upper respiratory tract, dyspnea, respiratory failure and glottis edema. There is a consensus that the efficiency of the treatment depends on the specificity and timeliness of the antivenom administered, associated with intense fluid therapy, colloid replacement, analgesics, diuretics and systemic antibiotics; the CFMB, (1995), in its list of indications for hyperbaric therapy, includes snakebite accidents.

ODUNAYO (2019) proposes that the dose of antivenom serum be one (01) vial per patient; but suggests that patients with lower body weight may require larger doses.



The last decades represented a period of strong expansion of veterinary hyperbaric services (MAZZI, 2020), with therapy resulting from a series of physiological and pharmacological mechanisms (THOM, 2009), and based on events in classical physics (BRASWEEL and CROWE, 2012); defined by SBMH (2018), as the inhalation of 100% oxygen with purity greater than 99%, concomitantly subjecting the


patient to an increase in the pressure inside the hermetic hyperbaric chamber.

The aim of this case report was to describe the early addition of hyperbaric oxygen therapy to the conventional treatment of a dog that was a victim of Bothrops envenomation and to evaluate the condition and remission of symptoms during the treatment performed.

## MATERIALS AND METHODS

A female Chihuahua dog, 6 years old, weighing 3 kg, was treated at a veterinary clinic. The owner reported that he witnessed the patient being attacked by a snake, managing to capture and photograph the animal (Figure 1). The victim quickly developed intense edema in the snout region, presenting agitation and difficulty breathing, and was immediately sent to the veterinary clinic.

**Figure 1.** (A) Aggressive agent, (B) Head anatomy, (C) Standard drawings.



*Fuente 1: Mazzi & Veiga, 2024.*

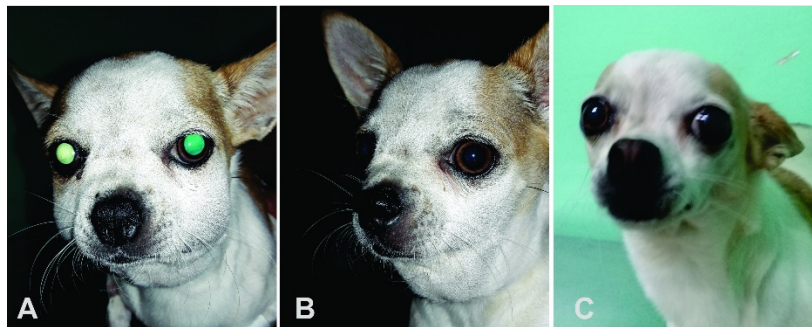
The attacking agent was identified as belonging to the Bothrops genus, its exact species was not identified. The clinical examination revealed the presence of 2 symmetrical perforations on the victim's snout, marked edema on the face and ventral cervical region, inspiratory

dyspnea with tachypnea and tachycardia, bilateral mydriasis, body temperature of 39.8°C and other parameters within physiological standards. Venous access was performed for fluid therapy with 0.9% sodium chloride saline solution, administration of prednisolone

0.5mg/kg, tramadol hydrochloride (2 mg/kg), ceftriaxone (25mg/kg) and polyvalent antivenom (30ml). No changes were observed in the blood clotting time test. After the patient started urinating, she was referred to hyperbaric treatment, where each lasted a total of 90 minutes, at a depth of 43 feet of sea water,

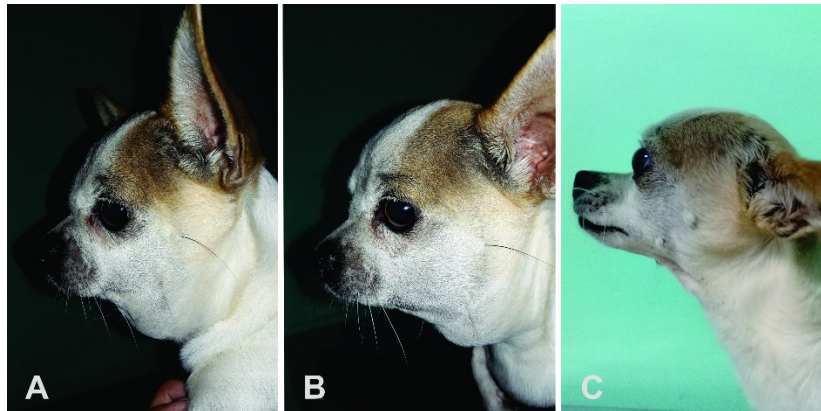
therefore at 2.3 ATA, without the need for sedation, daily, for a total of three treatments, with a photographic record being filed at each session and the general appearance (Figure 2) and specific facial edematous process and its expectation of necrosis (Figure 3) being assessed

**Figure 2. General aspect - (A) 1st day, (B) 2nd day, (C) 3rd day.**



*Fuente 2: Mazzi & Veiga, 2024*

**Figure 3. Edematous process - (A) 1st day, (B) 2nd day, (C) 3rd day.**



*Fuente 3Mazzi & Veiga, 2024*

## RESULTS

On clinical examination, the dyspneic, tachycardic and mydriatic symptoms resolved after the first session.

After the second hyperbaric treatment, the generalized edema of the face regressed, being restricted to the submandibular and ventral cervical regions. The patient presented normal eating of pasty food, active urination and subjective sensitivity in the muzzle region.

After the patient's 3rd pressurization, the edematous process reduced completely, and the patient was kept under observation and antibiotic therapy for another 2 days. She was normal and had no necrotic process or renal sequelae from the attack. She was released (Figure 4).

**Figure 4. Patient in the hyperbaric chamber.**



*Fuente 4: Mazzi & Veiga, 2024*

## DISCUSSION

It is undisputed that poisoning caused by snakes is an important problem in Human and Veterinary Medicine, due to its high incidence, severity and sequelae to those affected who always require urgent care.

SOARES et al., (2005), postulates that the only scientifically proven treatment for snake bites would be antivenom; but highlights as limiting

factors the early initiation of treatment and the specificity of the serum, as well as the uncertainty of the occurrence of the accident and the exact species of the attacker, basing the treatment on the symptoms expressed by the patient, on suggestive laboratory tests or guided by clinical and epidemiological criteria. In the occurrence analyzed, there was a



witnessing at the time of the attack and the careful preservation of the attacker, making it possible to verify the veracity of the fact and the identification of the variety of venom involved as being of the genus Bothrops; resulting in the maximum early and specific initiation of treatment.

FUNASA, (2001), confers a seasonality of snakebite accidents, based on climatic factors and the intensification of human activity in agriculture, attributing the highest rates of these accidents to the period between September and March; PINHO et al., (2004), corroborate this, attributing to the greater rainfall and temperature, extending the period of greatest snakebite cases until the month of April. The incident analyzed occurred in the second half of April, being at the limit of convergence with the literature.

TOKARNIA and PEIXOTO, (2006), correlate geographical aspects and snakebites, where virgin forests are home to 80% of non-venomous snakes and 20% of venomous ones, diametrically opposed, rural areas that have suffered human action have shown an inversion of 80% of venomous snakes to 20% of non-venomous ones; DALLEGRAVE and SEBBEN, (2008), corroborate this by stating that the disorderly advance of

cities over less populated areas has led to the finding of bothrops snakes on the outskirts of large centers, previously restricted to rural areas. This scenario of environmental degradation with subsequent urbanization is in perfect congruence with the habitat of the victim in this case report, which is the peripheral area of the federal capital of Brazil.

SAKATE, (2002), and PUZZI et al., (2008), attribute to the canine species an inherent curious behavior, which would lead to the greater involvement of the snout region in snakebites. The anatomical location evaluated in this case converges with such teachings.

The parameters of the clinical symptoms presented by the patient were the basis for classifying the severity of the incident, based on the scale proposed by LUCIANO et al., (2009), thus considered moderate to severe.

From the symptomatology developed by snake victims, a mosaic of variables is presented in the literature, with different sensitivity variations to botropic venom by certain species, in the individual peculiarities of the composition of the venom, varying between individuals of the same genus, resulting from the particular diet of each snake, but mainly varying through the amount of



poison inoculated in the victim, a fact of impossible determination, as highlighted by BICUDO, (2003) and corroborated in this report.

Singularly, the accident's promoter had been immediately identified as belonging to the botrops species; the formation of the conjecture about its genus was based primarily on MELGAREJO (2003), when describing the central-west region of Brazil as the habitat with the highest incidence of the genera *B. Moojeni* and *B. Neuwiedii*; in the analysis of the image of the snake, an adult-looking specimen was revealed; correlating this fact to the teachings of OLIVEIRA et al, (2003), there was the absence of coagulation disorders in this accident, the differential property of incoagulability evaluated in the specific accidents with smaller snakes as the author proclaims; the intense swelling in the victim's snout area converged to that proposed by SGARBI et al, (1995), when it attributes to the genus *B. Moojeni* the ability to cause edema with greater intensity when compared to the genus *B. Neuwiedii*, justifying in this way that the aggressor agent in this case, was an individual botrops, adult, genus *B. Moojeni*.

From the main characteristic of the effects of botropic poison, the outstanding necrotizing proteolytic

action was attributed by SAKATE (2002), to the direct cytotoxic action, causing a local reaction with pain, edema, congestion, hemorrhage and necrosis. In this case report, the evolution of symptoms diverged from that presented in the vast literature, with no proteolytic action of the poison, nor tissue necrosis in the areas adjacent to the attack, the absence of coagulation disturbances accentuated the observations of MO et al., (2018), when testifying its efficiency, having as its only differential the conventional treatment, the advent of hyperbaric oxygen therapy.

In analyzing the rapid regression of the edematous condition established in this case report, such efficiency converged with that proposed by MO et al., (2018), when describing the anti-edema effect of hyperbaric therapy in snakebite accidents.

MUKUNDAN et al., (2016), proposes that in humans, a minimum of six (06) hyperbaric sessions would be the tangible protocol to obtain a reduction in ophidian edema, in this case report a 50% reduction in the time of the protocol proposed by this author was observed; the discrepancy found reinforces the theory of different levels of response and sensitivity between species



subjected to treatment with hyperbaric oxygen therapy.

ODUNAYO (2019), argues that the antivenom dosage protocol is 1 vial/patient, but suggests that larger doses may be necessary for individuals with small body mass. In this report, the standard protocol was maintained, despite the patient's 3 kg body mass.

The decision to incorporate hyperbaric oxygen therapy into this treatment protocol was based on KORAMBAYIL et al., (2015), LACERDA et al., (2006), who confer antimicrobial properties to this therapy through the direct action of hyperoxia on bacteria, and describe relative hypoxia as the effect responsible for stimulating neovascularization and tissue hyperoxygenation; further reinforced by MORAIS et al., (2008), in the understanding that in the face of vasculitis of venomous etiology, the vital break in the vicious cycle of the ischemia would occur through the restoration of capillary angiogenesis promoted by hyperbaric oxygen.

Despite the considerable volume of literature produced and available in both human and veterinary medicine worldwide, addressing the issue of the undeniable benefits of hyperbaric oxygen therapy as a treatment for necrotic wounds caused by

snakebites, and which is a subject that has been largely controversial, since it is part of the guideline of the main global regulatory entities for the activity, the innovative nature of this approach stands out, not focused on the notorious capacity for scar stimulation, but rather on the early use of HBOT in snakebite accidents, preventing the progression of such accidents to predictable necrotic conditions; thus supporting future reviews on the choice of the appropriate clinical moment to opt for and establish this therapy.

Considering the high incidence of snakebites in both humans and animals worldwide, the relevance and severity that such cases represent, additional studies on the efficacy of early hyperbaric oxygen therapy for this clinical condition are necessary and urgent.



## CONCLUSION

In this case report, the early initiation of hyperbaric oxygen therapy proved to be a differential tool in the emergency treatment of snakebite with *Bothrops jararaca*, effectively combating edema and preventing progression to tissue necrosis, exceeding expectations in such a situation.

## CONFLICT OF INTEREST

The 1<sup>st</sup> author is an unpaid scientific consultant for BlueOcean- Hyperbaric Chambers, Colombia. There are no conflicts of interest to disclose.

## REFERENCES:

- BARNI, B. S., MOTTIN, I. B.; VIDOR, S. B.; ALBUQUERQUE, P. B.; CONTESINI, E. A. 2012. Incidência e perfil dos animais atendidos devido a acidente ofídico no Hospital de Clínicas Veterinárias da Universidade Federal do Rio Grande do Sul entre os anos de 2005 e 2010. *Acta Scientiae Veterinariae*, v. 40, n. 1, p. 1-2.
- BERROCAL, A., GUTIERREZ, J. M., ESTRADA, R. 1998. Snake envenomation in bovine. *Large Animal Practice*, v. 19, n. 4, p. 26-27.
- BLANCO, B. S., MELO, M. M. 2014. Animais Peçonhentos. *Cadernos Técnicos de Veterinária e Zootecnia. Projeto de Educação Continuada. CRMV-MG*, n.75, p.15- 26.
- BICUDO, P.L. 2003. Envenenamento em Animais Domésticos Causados por Serpentes, Artrópodes e Sapos. In: CARDOSO, J. L.C. et al. *Animais Peçonhentos no Brasil*. São Paulo: Sarvier, p. 437-49.
- BRASIL. 2005. Secretaria de Vigilância em Saúde. Departamento de Vigilância Epidemiológica. *Guia de Vigilância Epidemiológica*. 6. ed. Brasília: Ministério da Saúde; 816p.
- BRASWELL, C. CROWE, D.T. 2012. Hyperbaric oxygen therapy. *Compendium Continuing Education for Veterinarians*. Mar;34(3):p.1-6 .PMID: 22487778. <https://pubmed.ncbi.nlm.nih.gov/22487778/> acesso: em 15/12/2024.
- CFMB (Conselho Federal de Medicina do Brasil), Resolução nº1.457/95 [http://www.portalmedico.org.br/resolucoes/cfm/1995/1457\\_1995.htm](http://www.portalmedico.org.br/resolucoes/cfm/1995/1457_1995.htm) acesso: 20/08/2024.
- CHIPPAUX, J. P. 1998. Snake-bites: appraisal of the global situation. *Bull World Health Organ*. v.76(5). p. 515-24.
- DALLEGRAVE, E., SEBEN, V.C. 2008. Toxicologia clínica: aspectos teóricos-práticos. In: GONZALES, F.H.D., SILVA, S.C. *Patologia Clínica Veterinária: texto introdutório*. Porto Alegre. Universidade Federal do Rio Grande do Sul. p.145-210.



FERNANDES, T. A., AGUIAR, C. N., DAHER, E. F. 2008. Envenenamento crotálico: epidemiologia, insuficiência renal aguda e outras manifestações clínicas. Revista Eletrônica Pesquisa Médica, v. 2, n. 2, p. 1-10.

FERREIRA JÚNIOR, R.S., BARRAVIERA, B. 2004. Management of venomous snakebites in dogs and cats in Brazil. Journal of Venomous Animals and Toxins including Tropical Diseases., v.10, n.2, p.112-132.

FRANÇA, F.O.S., MÁLAQUE, C.M.S. 2009. Acidente botrópico. In: CARDOSO, J.L.C., FRANÇA, F.O.S., WEN, F.H., MÁLAQUE, C.M.S., HADDAD JR, V. (Ed). Animais Peçonhentos no Brasil – biologia, clínica e terapêutica dos acidentes. 2.ed. São Paulo: Sarvier. p.81-95.

FUNASA (Ministério da Saúde - Fundação Nacional de Saúde). 2001. Manual de Diagnóstico e Tratamento de Acidentes por Animais Peçonhentos. 2 ed. Brasília. p.120.

GOMES, R. C. B. 2008. Acidente botrópico, elapídico e crotálico em cães e gatos. 23f. Trabalho de Conclusão de Curso (Especialização em Clínica Médica de Pequenos Animais), Universidade Castelo Branco, Rio de Janeiro-RJ.

KORAMBAYIL, P.M., AMBOOKAAN, P.V., ABRAHAM, S.V., AMBALAKAT, A. 2015. A multidisciplinary approach with hyperbaric oxygen therapy improve outcome in snake bite injuries. Toxicology International, 22(1):104-109.

LACERDA, E.P., SITNOVETER, E. L., ALCANTARA, L. M., LEITE, J. L., TREVIZAN, M. A., MENDES, I. A. C. 2006. Atuação da enfermagem no tratamento com oxigenoterapia hiperbárica. Revista Latino-Americana de Enfermagem, janeiro-fevereiro; v.1, n. 14, p. 118-23.

LUCIANO, P. M., BARROS SILVA, G. E., AZEVEDO-MARQUES, M. M. 2009. Acidente botrópico fatal. Faculdade de Medicina de Ribeirão Preto. Revista FMRP.USP. 42 (1): 61-5

MAZZI, M.F. 2020. Oxigenoterapia hiperbárica veterinária. Revista Cães & Gatos VETFOOD. Ano 36, n. 251, jul, p.48-50.

MELGAREJO, A.R. 2009. Serpentes peçonhentas do Brasil. In: CARDOSO, J.L.C., FRANÇA, F.O.S., WEN, F.H., MÁLAQUE, C.M.S., HADDAD JR, V. (Ed). Animais Peçonhentos no Brasil – biologia, clínica e terapêutica dos acidentes. 2.ed. São Paulo: Sarvier. p.42-70.

MELO, M.M., SILVA JÚNIOR, P.G.P., LAGO, L.A, VERÇOSA JÚNIOR, D., HABERMEHL, G.G. 2004. Envenenamento botrópico. Cadernos Técnicos de Veterinária e Zootecnia. UFMG, n.44, p.59-79.



MÉNDEZ, M. C., RIET-CORREA, F. 1995. Snakebite in Sheep. *Veterinary and Human Toxicology*, v. 37, n. 1, p. 62-63. <https://pubmed.ncbi.nlm.nih.gov/7709596/>.

MO, LI., ZHI-HUI, XIE., AN-YONG, YU., DONG-PO, HE. 2018. Increased Efficacy of Antivenom Combined with Hyperbaric Oxygen on *Deinagkistrodon acutus* Envenomation in Adult Rats. *Chinese Medical Journal*. 131, (ISSUE3), p.323-329.

MORAIS, H.H.A., VASCONCELOS, B.C.E., VASCONCELLOS, R.J.H., CAUBI, A.F., CARVALHO, R.W.F. 2008. Oxigenoterapia hiperbárica na abordagem cirúrgica de pacientes irradiados. *RGO*, v. 56, n. 2. Porto Alegre. p. 207-212.

MUKUNDAN, P.K., AMBOOKAN, P.V., ANGAPPAN, R. 2016. Hyperbaric oxygen therapy improves outcome of snake envenomation: tertiary center experience. *Plastic and Anesthetic Research*;3:59-63. <http://dx.doi.org/10.20517/2347-9264.2015.11>

ODUNAYO, A. 2019. SNAKE ENVENOMATION. *Cliniciansbrief.com*. May. p.11-13. <https://files.brief.vet/2019-04/Snake%20Envenomation.pdf> Acesso: 20/12/2024

OLIVEIRA, R. B., RIBEIRO, L. A., JORGE, M. T. 2003. Fatores associados à incoagulabilidade sangüínea no envenenamento por serpentes do gênero *Bothrops*. *Revista da Sociedade Brasileira de Medicina Tropical*. 36(6):657-663, nov-dez.

PINHO, F. M. O., OLIVEIRA, E. S., FALEIROS, F. 2004. Acidente ofídico no estado de Goiás. *Revista Associação Médica Brasileira*. vol.50 no.1 São Paulo-SP. <https://doi.org/10.1590/S0104-42302004000100043>

PUZZI, M. B., VICARIVENTO, N. B., XAVIER, A., POLIZER, K. A., NEVES, M. F., SACCO, S. R. 2008. Acidentes Ofídicos. *Revista Científica Eletrônica de Medicina Veterinária*, v.6, n. 10, p. 1-7.

ROCHA, M.M.T., FURTADO, M.F.D. 2005. Caracterização individual do veneno de *Bothrops alternatus* Duméril, Bibron & Duméril em função da distribuição geográfica no Brasil (Serpentes, Viperidae). *Revista Brasileira de Zoologia*., v.22, n.3, p.383-393.

SAKATE, M. 2002. Terapêutica das Intoxicações. In: ANDRADE, S. F. *Manual de Terapêutica Veterinária*. 2ªed. São Paulo – SP: Roca. Cap 21, p. 545 a 547.

SAKATE, M. 2008. Zootoxinas. In: SPINOSA, H.S.; GÓRNIAC, S.L.; PALERMO NETO, J. (Ed). *Toxicologia Aplicada à Medicina Veterinária*. Barueri: Manole, p. 209-251.

SBMH- Sociedade Brasileira de Medicina Hiperbárica. 2018. Diretrizes de Segurança, Qualidade e Ética. 6ª Revisão. Disponível em: <https://sbmh.com.br/wp-content/uploads/2018/04/DIRETRIZES-2016-2018-28-11-17-Revisada.pdf> Acesso: 14/11/2024.



SGARBI, L.P.S. , ILIAS, M., MACHADO, T., ALVAREZ, L., BARRAVIEIRA, B. 1995. Human envenomations due to snakebites in Marília, State of São Paulo, Brasil. A retrospective epidemiological study. Journal Venomous Animals Toxins, v.1, n.2, p. 70-78.

SILVA, G.M.A., RODRIGUES, F. R., ANTONUSSI, T. D., CASTRO, K.F., DAN De NARDO, C. D., SALVADOR, R.C.L., GALVÃO, A. L. B. 2016. Acidente ofídico em cães – Estudo retrospectivo de casos atendidos no período de 2205 a 2015 no Hospital Veterinário “Dr. Halim Atique”. Revista Investigação Medicina Veterinária, São José do Rio Preto, SP, Brasil, 15(4):27-32.

SOARES, A.M., TICLI, F.K., MARCUSSI, S., LOURENCO, M.V., JANUARIO, A.H., SAMPAIO, S.V., GIGLIO, J.R., LOMONTE, B., PEREIRA, P.S. 2005. Medicinal plants with inhibitory properties against snake venoms. Current Medicinal. Chemistry. v.12, p. 2625-2641. <https://pubmed.ncbi.nlm.nih.gov/16248818/>

THOM, S. R. 2009. Oxidative stress is fundamental to hyperbaric oxygen therapy. Journal of applied Physiology, 106, 988-95.

TOKARNIA, C. H., PEIXOTO, P. V. 2006. A importância dos acidentes ofídicos como causa de mortes em bovinos no Brasil. Pesquisa Veterinária Brasileira. 26(2):55-68, abr./jun.

Juliana Horta Fernández MV - Physical Therapy and Veterinary Rehabilitation. Hyperbaric Medicine.



Grupo Andes – Investigación y Desarrollo en Medicina Regenerativa Veterinaria (C) Copyright (2025) Todos los Derechos Reservados

# 2. HIPERBARIC OXIGEN THERAPY OF BONE NON-UNION ASSOCIATED WITH POSSIBLE OSTEOMYELITIS



**MV July Horta Fernández**

Physical Therapy and Veterinary Rehabilitation.  
Hyperbaric Medicine.  
Colombia

## INTRODUCTION

Non-union is defined as a failure of fracture healing, in which all signs of repair cease, and which may be the result of several factors, such as inadequate stabilization, poor vascularization, excessive interfragment distance, infection (osteomyelitis), concomitant local or systemic disease, and other idiopathic factors.

Bone infection (osteomyelitis) can develop as a complication of orthopedic surgery or as a consequence of an infection in the adjacent soft tissues, usually associated with trauma.

Hyperbaric oxygen therapy is a complementary treatment that can promote bone healing by increasing the partial pressure of oxygen in the tissues, promoting the osteoblastic process and enhancing the body's self-defense response.

### ***Clinical case***

Nacho, an 8-month-old male Labrador cross, was referred to ReInVet - Comprehensive Veterinary Rehabilitation - for management of a 3-month-old forelimb lameness resulting from a fracture in the distal third of the humerus (Image 1) caused by a car accident. The fracture was surgically treated twice until the decision was made to remove the orthopedic hardware (Image 2). Pre-consultation x-rays showed changes suggestive of osteomyelitis and non-union (Image 3).



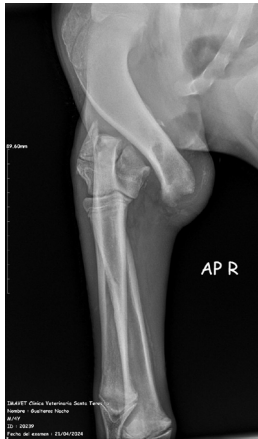

Image 1

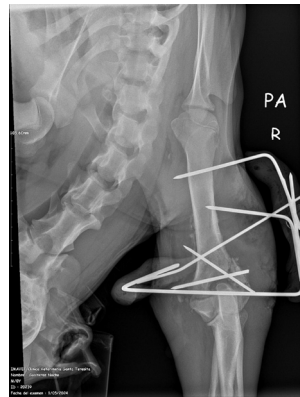


Image 2

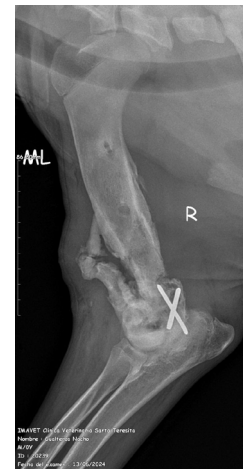

Image 3

The kinesiological examination revealed a  $\frac{3}{4}$  lameness of the right forelimb, severe thickening with increased temperature of the middle and distal third of the right humerus, an increase in size on the medial aspect of the elbow, a lesion on the lateral aspect of the humerus, thinner and purple skin, with slight accumulation of subcutaneous fluids, decreased flexion and extension of the elbow, with pain upon movement, mild proprioceptive deficit and moderate hypotrophy of the affected limb.

Hyperbaric oxygen therapy at 2.2 ATA for one hour, once a week, was initiated (Image 4). Radiographic follow-up was performed after the fourth session (Image 5), which showed the beginning of bone tissue rearrangement, and another image two weeks after the ninth session, which showed that the fracture was



consolidated and there were no changes suggestive of osteomyelitis (Image 6). At this point, a new examination was performed, in which recovery of dynamics, improvement in weight bearing and in the proprioceptive deficit were observed, so the rehabilitation process was continued with hydrotherapy on an underwater treadmill (Image 7).

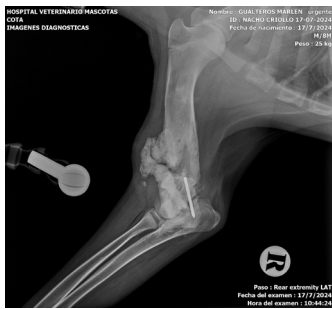

Image 5

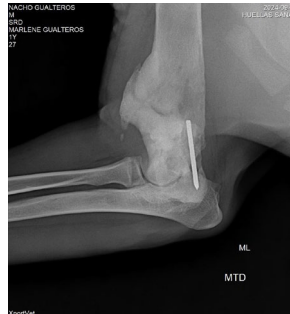

Image 6

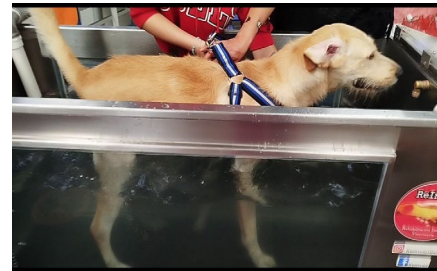

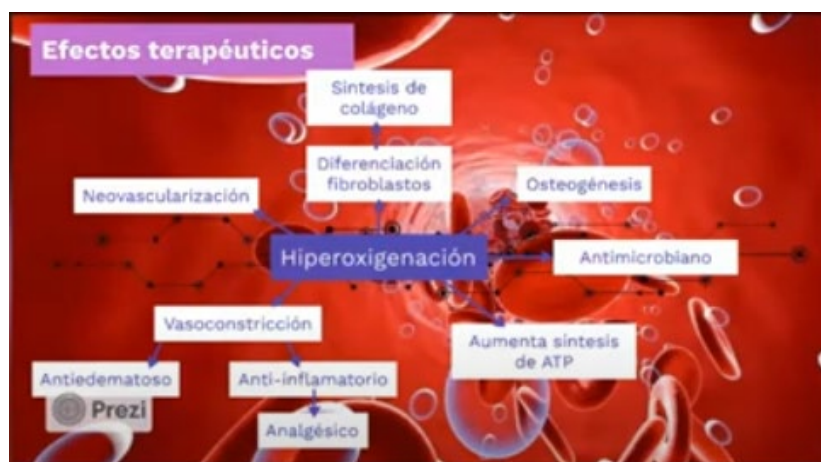Image 7

## Conclusions

Hyperbaric oxygen therapy (HBO) is a little-known tool for the treatment of osteomyelitis. Its operation is based on the laws of gas physics, which result in an increase in tissue oxygen concentration, stimulating the release of growth factors that promote healing and restoring numerous cellular functions in affected tissues. It also enhances the phagocytic capabilities of polymorphonuclear neutrophils, among other actions.

To perform this therapy, the patient remains in a hermetically sealed environment, where 100% medical oxygen is administered and the atmospheric pressure inside the chamber is increased. These two conditions significantly increase the partial pressure of oxygen in the tissues, increasing its bioavailability (hyperoxygenation), which results in the following therapeutic effects:





- It contributes to the formation of new blood vessels.
- It increases fibroblast differentiation, thereby promoting, in an orderly manner, collagen synthesis, which, together with neovascularization, favors the healing process.
- Stimulates osteogenesis.
- It improves the conditions for defense cells and prevents the growth of anaerobic bacteria (antimicrobial effect).
- Increases ATP synthesis: improves metabolic processes.
- Vasoconstriction: Anti-edematous, anti-inflammatory and analgesic effect.

In this case of non-union associated with possible osteomyelitis, the use of hyperbaric oxygen therapy (9 sessions) was decisive in the resolution of the fracture and helped in the disappearance of the radiographic findings associated with osteomyelitis, which opens the possibility of this type of complementary therapy being taken into account in future similar cases.

examination revealed a  $\frac{3}{4}$  lameness of the right forelimb, severe thickening with increased temperature of the middle and distal third of the right humerus, an increase in size on the medial aspect of the elbow, a lesion on the lateral aspect of the humerus, thinner and purple skin, with slight accumulation of subcutaneous

fluids, decreased flexion and extension of the elbow, with pain upon movement, mild proprioceptive deficit and moderate hypotrophy of the affected limb.

**Editor's Note:** Everything expressed in this article is the author's opinion and field experience.



**Dr. David Ré**  
Biomedicina Veterinaria

**Consultorio Veterinario**  
**Dr. DAVID RÉ**

11 51829194 / 11 31453577

Pilar, Buenos Aires, Argentina.

[www.biomedicinaveterinaria.com.ar](http://www.biomedicinaveterinaria.com.ar)

**Medicina interna**  
**Ozonoterapia**  
**Terapia Neural**  
**Medicina regenerativa**  
**Ortobiofisiatria y terapias avanzadas**  
**aplicadas a la Medicina Interna**

**DR. DAVID JOSE MARIA RE M. V. DIP. M.P. 10537 USAL ARG. BS. AS.**  
**DIP EN CITOLOGIA / LABORATORIO / MEDICINA INTERNA**  
**(UNIVERSIDAD DEL CENTRO DE LA PROVINCIA DE BUENOS AIRES).**  
**DIP EN ORTOBIOFISIATRIA. GRUPO ANDEZ (UNIVERSIDAD CATOLICA DE CUYO).**  
**ESPECIALISTA EN OZONOTERAPIA**  
**(COLEGIO AMERICANO DE PROFECIONALES EN OZONO AC).**



Grupo Andes – Investigación y Desarrollo en Medicina Regenerativa Veterinaria (C) Copyright (2025) Todos los Derechos Reservados

# 3. CLINICAL CASE OF NERVOUS CANINE DISTEMPER TREATED WITH PHYSIATRY AND OZONE THERAPY



## **M.V. Julieta Viano**

Researcher at Grupo Andes  
Medical Director at the Veterinary  
Physiotherapy Center. Rio IV - Córdoba,  
Argentina



1: Wendy

Female, canine approximately 1 year old. Mixed race. Whole.

She was found abandoned in January 2025, after having given birth to several puppies.

Clinical diagnosis of nervous distemper.

Distemper testing is not performed; diagnosis is based on clinical signs and the patient's progress.

## DISTEMPER

Is an inflammatory, demyelinating disorder of the central nervous system (CNS), with impaired myelin production due to viral replication in the white matter. Not all patients present neurological signs, but those who do experience myoclonus have passed the acute phase. It appears to originate from focal lesions in the spinal cord or basal ganglia, which induce lower motor neuron hyper excitability.



At the Physical Therapy consultation, the patient presented with myoclonus throughout the body, marked in the head and neck and hind limbs, with flexion of the same and retraction of the extensor muscles, predominantly in the right hind limb.

Resultados:

HEMOGRAMA COMPLETO: ESPECIE: CANINO

ERITROGRAMA		Valor de referencia	LEUCOGRAMA		Valores de ref./µl
Eritrocitos/µl	5.260.000	5.5-8.5 10 <sup>6</sup> /µl	Leucocitos/µl	9.100	6.000 - 18.000
Hemoglobina g/dl	11,5	12 - 18	%		
Hematocrito %	37,49	37 - 55	Mieloblastos		
V.C.M. fl	71	60 - 77	Promielocitos		
H.C.M. pg	21,9	19.5 - 24.5	Mielocitos		
C.H.C.M. %	30,7	32 - 36	Metamielocitos		
Reticulocitos % /µl	-	Hasta 1	Neutrófilos Baciliformes		Hasta 300
T.R.C.	-	-	N. Segmentados	54	5.888
I.P.R.	-	-	Linfocitos	12	1.104
GR. Nucleados/100 L	-	-	Monocitos	12	1.104
P. Plasmáticas g/dl	8,0	5.3 - 7.9	Eosinófilos	12	1.104
Fibrinógeno mg/dl	100	100 a 400	Basófilos		0 a 50
Rel. Pp/Fibr.	-	-	Plaquetas/µl	583.000	150-500 10 <sup>3</sup> /µl

OBSERVACIONES AL MICROSCOPIO:

His condition is alert, he has superficial and deep pain, he can stand up with his front limbs but his hind limbs are flexed with muscle retraction and he cannot extend them.



ANÁLISIS DE LABORATORIO PARA MANEJO Y PREVENCIÓN DE ENFERMEDADES

Med. Vet. Sandra Botello | Lic. 0192  
San Vito 955 - Call 0182 85548904  
e-mail: laboratorio@grupandes.com  
Rta. Coarale, Cabañete

Serie eritrocitaria: Anisocitosis. Anemia leve normocítica hipocrómica.  
Serie leucocitaria: S/P.  
Serie plaquetaria: Elevada cantidad de plaquetas.

**BIOQUÍMICA SANGÜINEA:**

Determinación: Valor de referencia:

Urea mg/dl:	29,11	20 - 50
Creatinina mg/dl:	0,67	0,6 - 1,4
GOT UI/l:	67,10	13 - 70
GPT UI/l:	25,66	17 - 78
FAS UI/l:	539,19	Hasta 200

Distemper is an inflammatory, demyelinating disorder of the central nervous system (CNS), with impaired myelin production due to viral

replication in the white matter. Not all patients present neurological signs, but those who do experience myoclonus have passed the acute phase. It appears to originate from focal lesions in the spinal cord or basal ganglia, which induce lower motor neuron hyperexcitability.

After 3 physical therapy sessions, he has managed to get up faster, with more strength, his myoclonus has slightly decreased, and he can walk with his left hind limb but with the limb flexed.

Treatment with physical agents;

Transcranial magnetic fields, laser therapy and tens.

Intrarectal ozone therapy.

Transcranial photobiomodulation (laser, LED) is a noninvasive method that, when applied directly to the head, increases blood circulation and oxygen flow to the tissues. It has an anti-inflammatory and neuroprotective effect.

It reaches the cortex, partially reaching the outermost neurons, with a neuroprotective effect before the light reaches the brain. In canines, it is used in the frontal and occipital regions. Low frequencies are applied in a pulsed manner to achieve



greater penetration depth with a short exposure time.

Transcranial magnetic stimulation is a noninvasive method for electrically stimulating the cerebral cortex and assessing the excitability of the motor cortex and corticospinal tract. It can be delivered using single pulses, pairs of stimuli separated by variable time intervals to the same or different regions, or via trains of stimuli at variable frequencies. Lower frequencies have greater tissue penetration.

When the brain is stimulated transcranially, a complex sequence of events ensues, with both excitatory and inhibitory effects. These effects depend on the intensity of the stimulus and the excitability of the cortex and spinal cord.

TENS is used paravertebrally at the level of the cervical and thoracolumbar spine, since the

patient's position causes pain referred to palpation of the spine.

Ozone therapy is administered intrarectally at a concentration of 20 mcg/ml. Due to the patient's size, 120 ml is administered. Ozone achieves greater oxygenation of all tissues by absorbing it in the rectal ampulla, providing a systemic effect.



Your advertising could be here



Grupo Andes – Investigación y Desarrollo en Medicina Regenerativa Veterinaria (C) Copyright (2025) Todos los Derechos Reservados

## Reference

1. Transcranial Magnetic Stimulation, M.A. Ibiricu; G. Morales, Clinical Neurophysiology Service, Virgen del Camino Hospital, Pamplona. 2009
2. Transcranial magnetotherapy as a therapeutic alternative for psychophysiological insomnia, C. Martinez Hidalgo; T. Virues Alba; R. Alessandrini; A. Sentmanat Belison; J. Torres Hernandez. 2002
3. Magnetotherapy: Review of its different applications in neurological diseases, S. Mercado Saenz; F. Morales Moreno; M.J. Ruiz Gomez, Department of Radiology and Physical Medicine; Faculty of Medicine - University of Malaga 2008.
4. Neurological and psychological applications of transcranial lasers and LEDs, J.C. Rojas; F. Gonzalez Lima, <https://doi.org/10.1016/j.bcp.2013.06.012>
5. Transcranial laser stimulation improves human cerebral oxygenation, Fenghua Tian PhD, Snehal N. Hase MS, F. Gonzalez-Lima PhD, Hanli Liu PhD, 2016 <https://doi.org/10.1002/lsm.22471>
6. Transcranial photobiomodulation (laser) therapy for cognitive impairment: A review of molecular mechanisms and potential application to canine cognitive dysfunction (CCD), Curtis Wells Dewey; Matthew Warren Brunke; Kasie Sakovitch; Open Veterinary Journal. 2022
7. Challenges of transcutaneous laser application for the potential of photobiomodulation of the spinal cord at the scale of a large companion animal, Daqing Piao, Lara A. Sypniewski, Kenneth E. Bartels, Mechanisms of Photobiomodulation Therapy XII; 100480M (2017), <https://doi.org/10.1117/12.2248164>
8. Ozone therapy in veterinary medicine: clinical indications and techniques, Juliana Midori Sumida; Ayne Murata Hayashi Universidade de São Paulo.2022, <https://doi.org/10.21708/avb.2022.16.4.10330>
9. Has Ozone Therapy a Future in Veterinary Medicine?, Süleyman Kozat and Eda Nur Okman, Journal of Animal Husbandry and Dairy Science, Volume 3, Issue 3, 2019, PP 25-34

Leyes Obreras & Luis Reunaidi  
Río IV - Córdoba  
Argentina



Grupo Andes – Investigación y Desarrollo en Medicina Regenerativa  
Veterinaria (C) Copyright (2025) Todos los Derechos Reservados

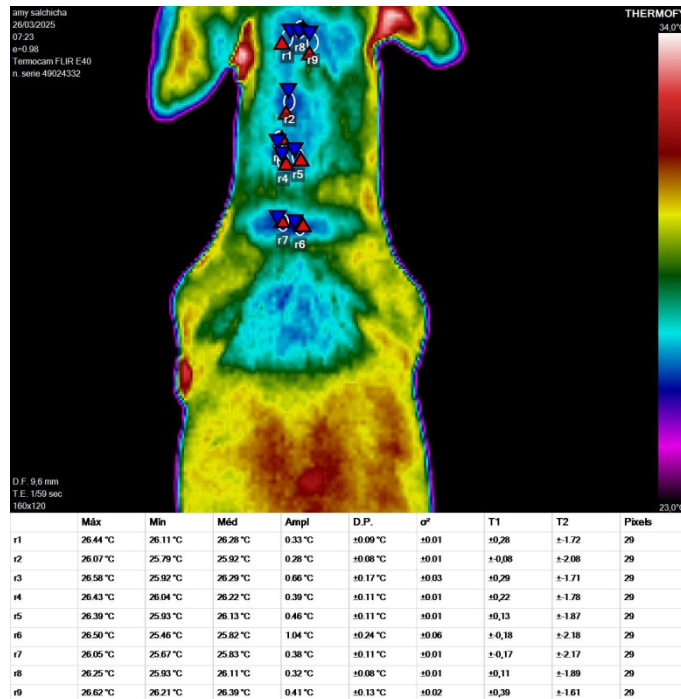
# 4. TERMOGRAPHY IN ANIMAL MEDICINE IN A NUTSHELL



## M.V. Felix Cardenas

Medical director at Beckenham Centro de Salud Animal  
Director of the Andes Group – Chile Division

We all know that thermography, or thermology, is the branch of science that uses infrared data collected from the skin and then digitally displays it to represent changes in the body's surface, allowing us to identify variations in vascularization between deep and superficial plexuses. For decades, thermography has been a constantly evolving technique open to technological improvements and diagnostic possibilities in medicine, referring to medicine as a single large area of animal and human health.



Neck thermography of a patient who suffered a stroke

But it is clear that, like other imaging or medical procedures, thermology must have a pattern or method of implementation that ensures an interpretation of what



we are seeing, bringing us closer to the possibility of a positive relationship with other imaging or treatment based on confirmation of a previous doubt.

In the previous paragraph, I wrote the word "diagnostic" in quotation marks. I did so intentionally, since in some talks or videos by professionals who perform this technique, they refer to it specifically as a diagnostic technique. In particular, in my experience in orthobiophysiatria, I would describe it as the best friend anyone working with the musculoskeletal system could have. There are countless cases in which a set of thermographic images and their report has led to confirmation and expansion of radiological diagnoses through new views added to those previously taken. Between ten and fifteen patients per week are referred for musculoskeletal ultrasounds to supplement the information they originally brought to us. If we think of spondylosis, its thermological differences can produce high or low totals, with different radiances, which leads us to suspect acute or chronic conditions. Just imagine that as an informative product of this supplement, we can comfortably work on subsequent stem cell transplantation in those cases whose original diagnosis has now become a complete description of a past, with potential predictive value if we do nothing.

It all starts with selecting the right team based on our needs and goals. It's also helpful to consider whether we want to publish case studies or other studies. The way we work, the software, space limitations, or the environmental conditions of our work.



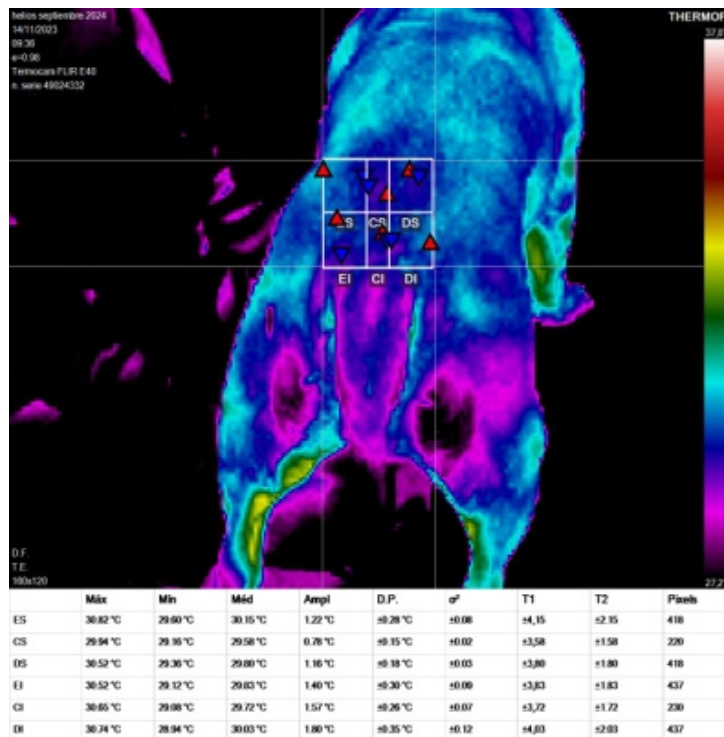
FLIR ONE PRO



FLIR ONE

Professionally, they can be limiting or reinforcing for and in our professional work.

There are devices of sizes that are comfortable, maneuverable or that can be transported by those professionals who get on and off airplanes, some that require taking screening type images , others that need better quality images and others that can even investigate and confirm new uses for medical thermography .



Dorsal image of a canine patient in which damage to the lumbar area is present.

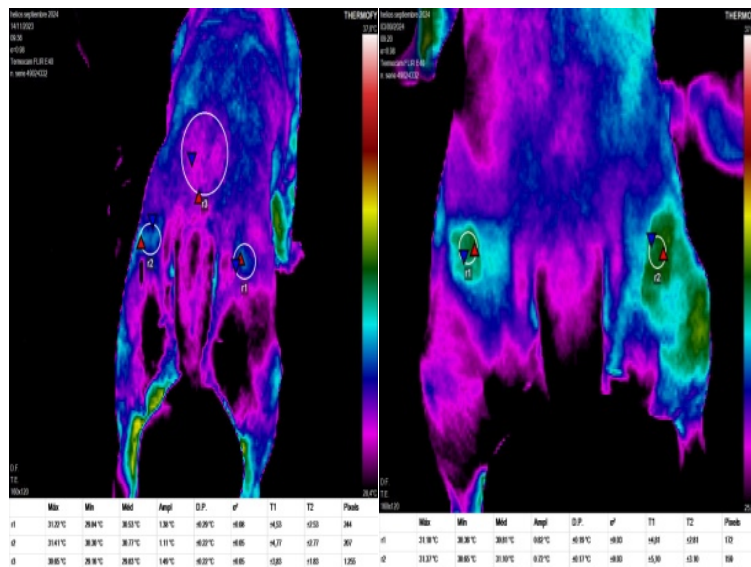


The different models also have differences between them, such as the quality available in the universe of pixels, the versatility in the use of the Internet, the security of the definition on the edges of the images, the possibility of making videos or even streaming.

Thermology videos are practical and offer the opportunity to analyze the versatility of movements associated with the world of peripheral vascularity, since observing changes in radiance in a walking patient reveals the behavior of a particular limb in the context of the gait cycle.

A video can offer the benefit of obtaining numerous thermal images in an ordered sequence. That is, from a single minute of recording, you could have hundreds or more images to analyze and obtain deeper answers, versus the single image you can obtain by shooting in a particular position.

Streaming is very useful for those who have contact with patients miles away. No trained interpreter is required; all you need is yourself. On the other side, thousands of miles away, the patient is met by someone who knows how to operate the equipment, the concept of streaming, and masters the positions along with the basic regulatory conditions for taking thermal images. That's what's needed.




Measurement of before and after cell therapy in tissues.



The professional receiving what's happening remotely is the one who will receive the information on which they will make a judgment. This information will be received in the form of videos or images, which they will save for later analysis.

The videos should ideally be performed at a regular speed, with a constant incline, and under controlled environmental conditions. Otherwise, the patient may accelerate their walking, jogging, or running at some point. This gives us an idea that a dry treadmill is the best option in a controlled environment.

In animal medicine, where patient trust in their guardians is vital, the presence of the professional, the patient, and "their guardian" in the thermostable room can trigger a fear reaction, an inability to remain still, and an increase in catecholamines, which can change the caliber of blood vessels, especially peripheral ones, in both plexuses—vital material and the reason for the interpretation of changes in thermology.



The positions should be as straight as possible, with the patient very still.

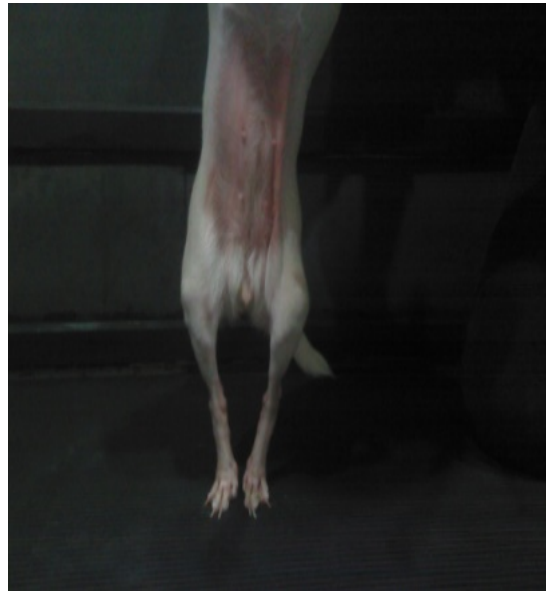The "standing still" position should be understood because, as a medical image, there are regular and normal positions. If you are someone familiar with X-ray views, consider for a minute that the same thing happens in this area of medicine.



Grupo Andes – Investigación y Desarrollo en Medicina Regenerativa Veterinaria (C) Copyright (2025) Todos los Derechos Reservados

Not exactly the same views or positions. There are also focal distances determined by the equipment model and the image clarity associated with pixelation

The thermostable room is the place we must implement as responsible professionals. Perhaps you might even be surprised that the further I am from the thermostable room standard when taking my thermographic images, the closer I am to presenting reports that are unrelated to the vascular truth in which I am situated; and to being able to talk about inflammation as a general topic, since the mere presence of sunlight, warm artificial light, light reflections, or light rebound ruins the possibility of accuracy in the subsequent medical report.



The cover of this room prevents light from bouncing back towards the thermal sensor.

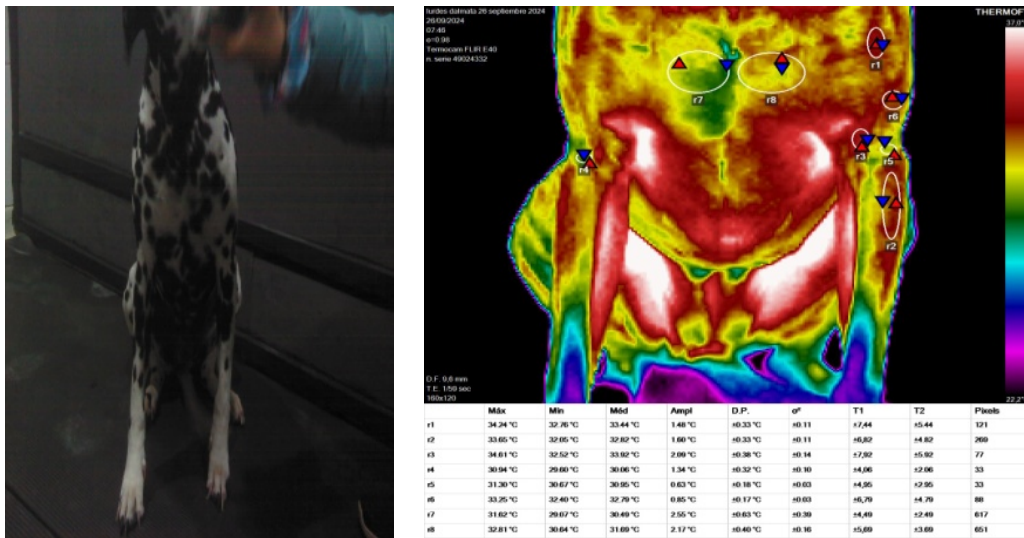
From this comes the concept that taking thermographic images outdoors is considered a "snapshot" that can lead us to suspect a physiological change. In racehorses, thermography is used in places without ambient thermal equilibrium, but we must remember that there are generally full teams of imaging experts available to assist and guide us when we see "something" in the thermography . However, at the same time, the risk and margin of error are high without a suitable room.



In my experience, I call it, as I noted a few paragraphs ago, my best imaging friend. For ethical reasons, I refuse to work with patients without thermal imaging, which I take in my temperature-balanced room, using ambient thermal values that scientifically reflect the vascular balance of the plexuses.

The list of patients who come with a fixed diagnosis, with a set of x-rays for example, increases weekly, and in approximately 7 days, we have been able to obtain a description.

complete information on what happens in the joints, areas of the spine or central axis and integuments in general.

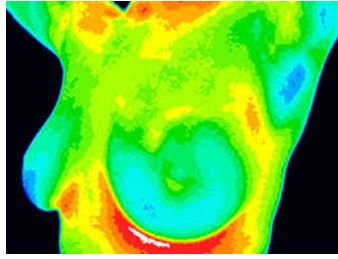


Patient with elbow dysplasia, who also presented pectoral dysfunction also visible in thermology.

The future is looking bright. The use of concepts like mountain biking, breast thermology, and predictive spinal analysis using thermology are important steps forward.

Of course, these processes have already begun in humans. Breast thermology is an excellent tool for providing complementary analysis to regular mammography.

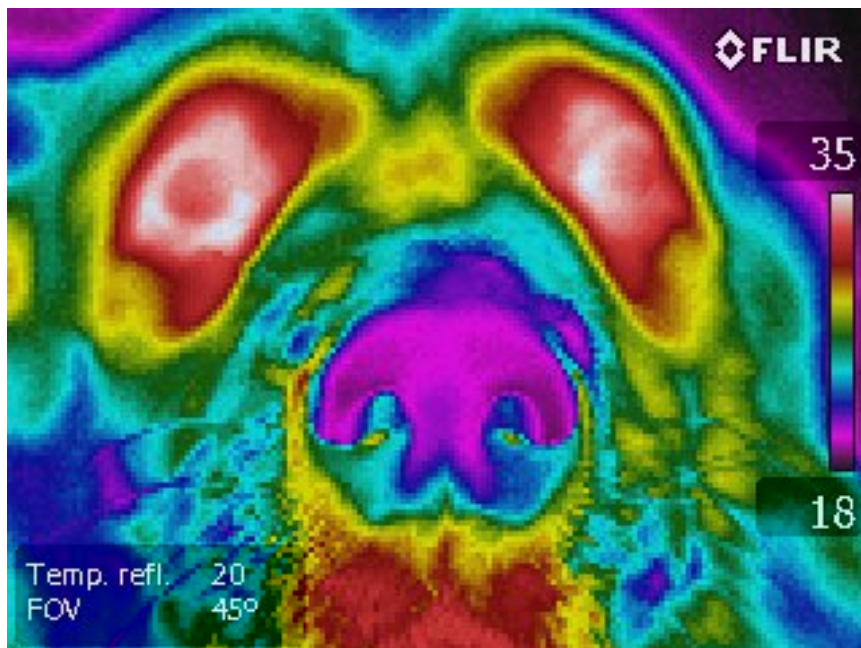




We can understand that by combining an examination as important as mammography with a set of images that demonstrate a detailed vascular analysis, we also have incredible screening with predictive value.

There are certain characteristics, such as glandular arrangement, software use, hormonal characteristics, and sexual cycles of

the female and/or female dog; births versus sterilization in animals. So, it's a universe of very useful information, but in animals, it adds a bit more complexity to analyze beforehand, since our patients are beings who can even have pregnancies until advanced age, and hormonal stages produce conditions in the vascularization and tissues of these glands.

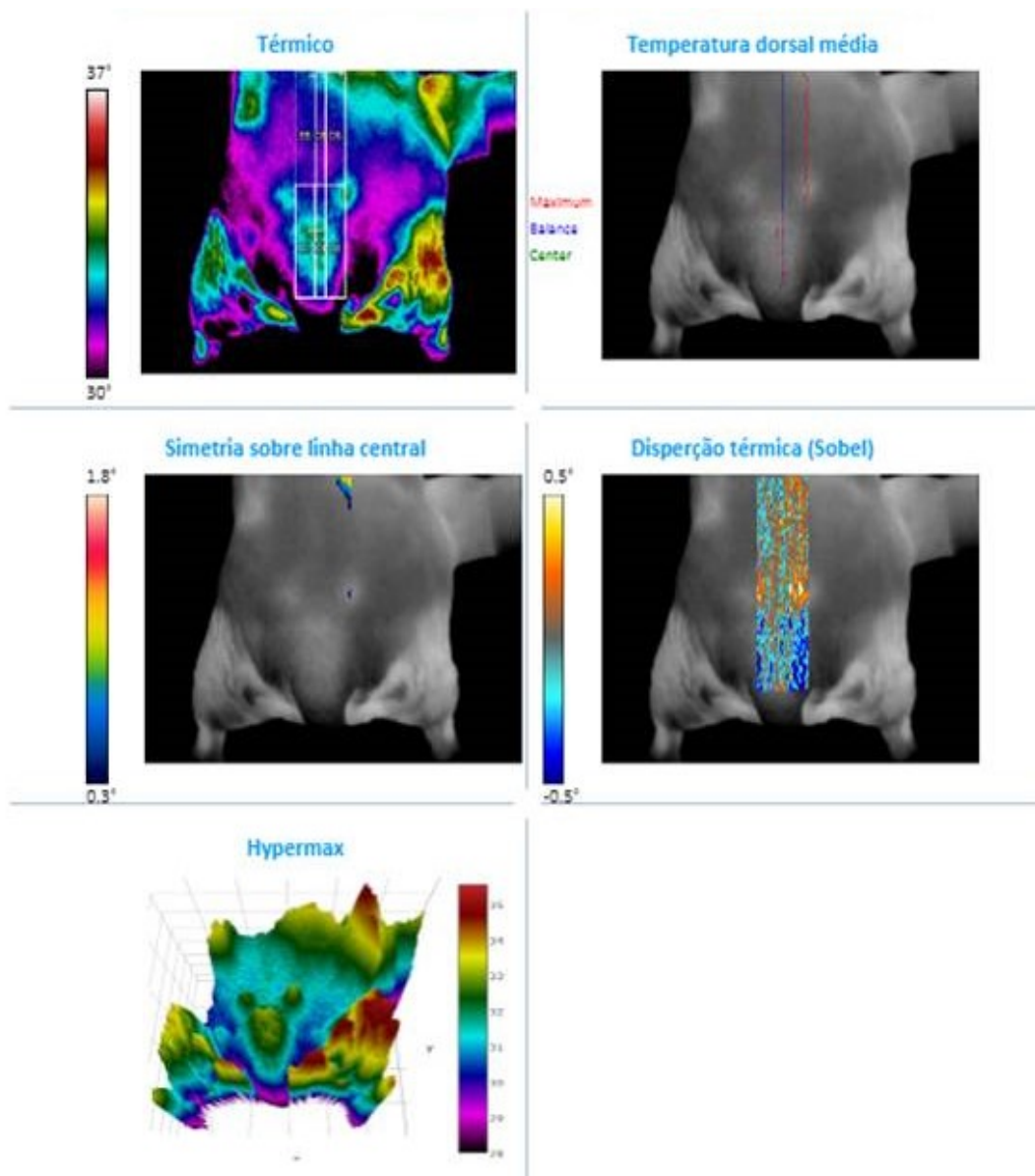


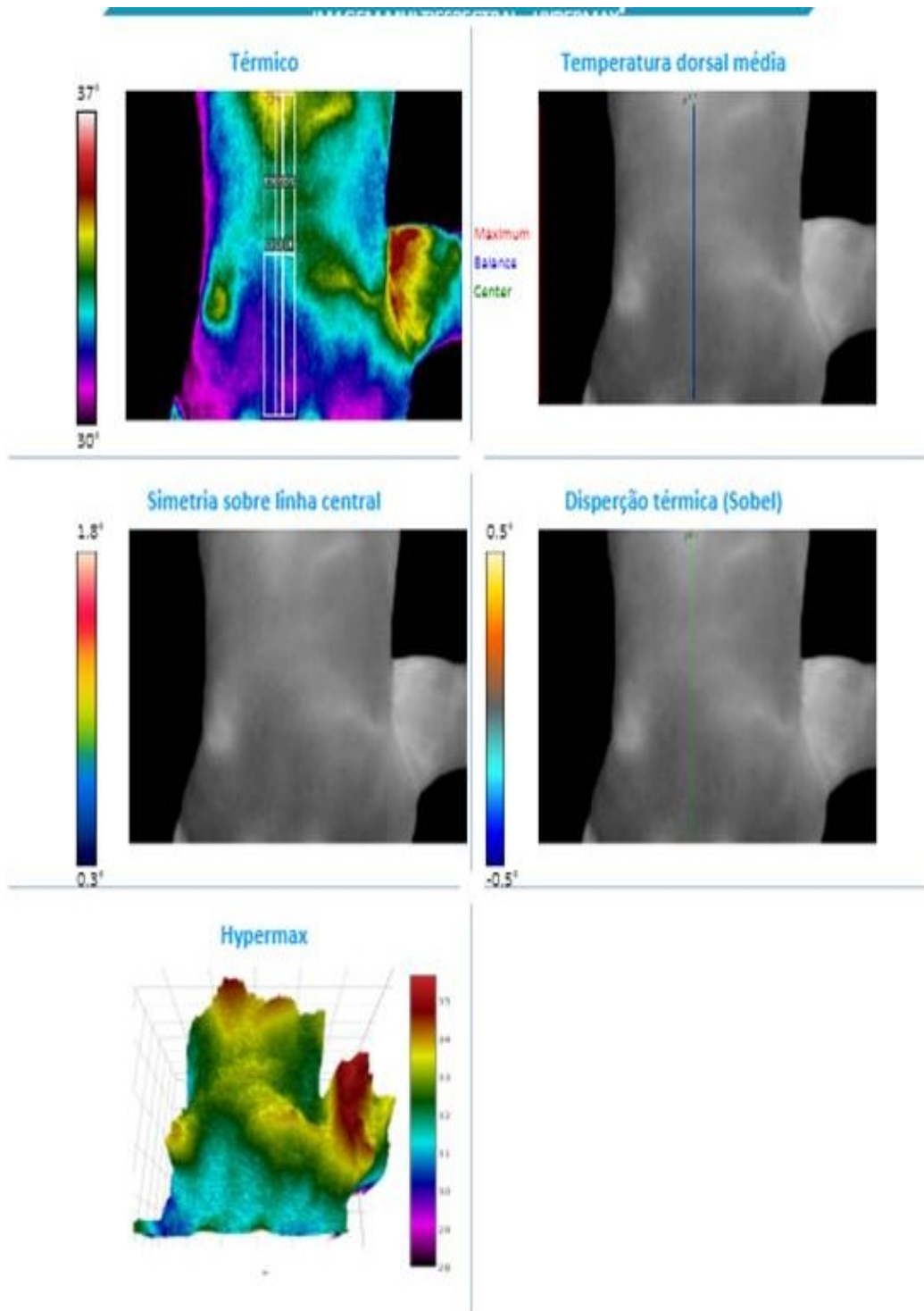
Moment before BTT thermal analysis in a patient with stroke



BTT tables already exist for humans. And we are currently developing our own in animals. To put it simply, it involves measuring and subsequently calculating cerebral circulation to identify the characteristics of patients with hypo- or hypermetabolic activity, certain

cardiac conditions, and even strokes. It's quite a challenge, but it can build a bridge that can more quickly connect advanced physical rehabilitation centers with cardiologists, endocrinologists, or neurologists, thereby improving treatment conditions.





While the two images we published above are not the product of a standard thermological analysis, they are part of the possibility of processing a thermological image of the back using special software. Using this software's

Artificial Intelligence calculations, a predictive result of possible spinal pathology can be obtained based on balance, asymmetries, and vascular changes, which are the basis of physiology.

We must be vigilant. The changes are coming rapidly. And we cannot remain on the sidelines.



Grupo Andes – Investigación y Desarrollo en Medicina Regenerativa Veterinaria (C) Copyright (2025) Todos los Derechos Reservados

# 5. THE REGENERATION DILEMMA: ADVANCES AND CHALLENGES IN VETERINARY CELL THERAPY



**MV Esp. Juan José Aversa**

Medical Director at IntegraVet Center for Physical Therapy & Veterinary Regenerative Medicine

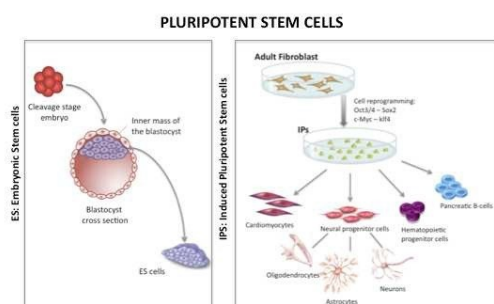
Director of the Andes Group, Argentina division

For a better introduction, it is important to define regenerative medicine.

This field is built by combining multiple elements, including living cells, a supporting matrix (i.e., a scaffold), and cellular communicators (or signaling systems) that stimulate cells and their environment to grow and develop into new tissues or organs. Indeed, regenerative medicine is an emerging multidisciplinary field involving biology, medicine (human and veterinary), and engineering, and is likely to revolutionize how we improve the health and quality of life of millions of patients worldwide, regardless of species, by restoring, maintaining, or improving tissue and organ function.

We will address some aspects of regenerative medicine, highlighting the main advances and remaining challenges in cell therapy (including cell communicators) and tissue and organ engineering.

## Cell replacement therapy



*2(Image: adapted from Sigma-Aldrich).*

The cell types used depend on the type of tissue that needs to be repaired. Several cells have been suggested as suitable for cell therapies: for example, embryonic stem cells (ES), induced pluripotent stem cells (iPSCs), and somatic stem cells from fetal or adult tissues. The potential use of fetal tissue or differentiated embryonic stem cells from allogeneic sources

presents limitations due to tissue availability, ethical concerns, or safety issues.



Grupo Andes – Investigación y Desarrollo en Medicina Regenerativa Veterinaria (C) Copyright (2025) Todos los Derechos Reservados

In contrast, adult somatic stem cells can be used in autologous grafting procedures, avoiding patient immunosuppression.

### ***Cellular communicators***

The circulatory system is involved in the transport of a wide variety of biological molecules and cells and can be considered the body's basic communication system.

Cellular communicators act as a signaling system that stimulates cells to act.

In some cases, these communicators may lead cells to integrate damaged tissues and rebuild lost connections; however, some signals may also induce cellular stress responses that lead to cell death.

### ***Tissue engineering*** or... where biology meets engineering.

All cells within tissues are separated and interconnected by a matrix, or scaffold. The consistency of the matrix can vary from liquid, as in blood; to semi-solid, as in cartilage; to solid, as in bone. Tissue engineers implant cells into a matrix or create the appropriate conditions for living cells to build their own three-dimensional matrix. This matrix provides the structure that supports the cells and creates the physiological environment for them to interact within the host tissue. The success or failure of an implant material in the body depends on a complex interaction between a synthetic "foreign body" and the "host tissue," involving not only biological factors but also mechanical, physical, and chemical factors.

### ***Current state of the art***

Researchers from around the world are working daily to find new alternatives for cultivating, expanding, preserving, and applying stem cells to various veterinary patient conditions.

Japanese researchers have developed an effective, noninvasive, and painless method for reprogramming canine stem cells from urine samples, transforming them into an induced pluripotent stem cell (iPSC). This technique has been widely used in human regenerative medicine studies.



We cannot definitively say which specific diseases these technologies will treat. However, it is known that red blood cells can be produced from iPSC cells from canine patients, so they could be used to treat anemia. There is also the possibility of creating pancreatic cells to treat canine diabetes.

In our case, the Andes Group research team developed a protocol for the treatment of chronic kidney disease in felines, based on cells from the stromal vascular fraction obtained mechanically through adipose tissue, obtaining encouraging results for the treatment of patients with stage 2.

The application of micronized adipose tissue (mFAT) in pathologies such as anterior cruciate ligament injury (ACL), elbow/hip dysplasia, and elbow/knee/hip osteoarthritis in canines has demonstrated the effectiveness of the treatment in restoring quality of life to these patients.

It has also allowed surgical techniques such as FORAGE to be modified so that autologous orthobiological products such as concentrated bone marrow aspirate (BMAC) are applied in the generated foramen at the same time, to provide a solution to ischemic necrosis of the femoral head (Aversa, Albornoz 2022).

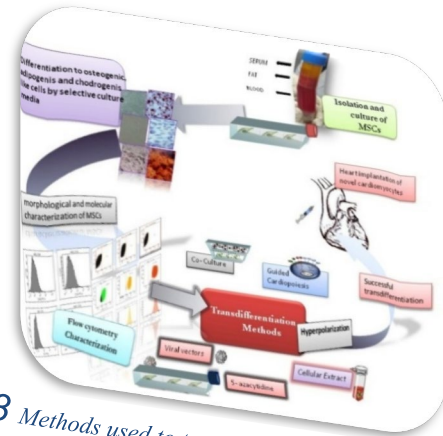
Or techniques such as organ decellularization offer hope for patients who require a donation and who, due to the complexity of tissue compatibility, are unable to obtain it in time. Decellularization allows for the production of scaffolds from a donated organ, which can then be recellularized with autologous stem cells (a fundamental step in tissue engineering), thus allowing for the production of a 100% compatible organ, since the patient's own stem cells differentiate into the cell lineage corresponding to the organ. The legend of Promethean liver regeneration ceases to be a myth and becomes a reality.

Your advertising could be here



Hydrogels containing umbilical cord stem cells have demonstrated their efficacy and efficiency in the treatment of cardiac pathologies such as myocardial infarction or dilated cardiomyopathy in monkeys, which has allowed their transposition to human patients (Zimmermann WH, January 2025).

Mononuclear cells from bone marrow or umbilical cord are used today to make eye drops that allow the regeneration of corneal tissue in an ulcer, so common in veterinary patients (Mengyuan Wang et al 2023).

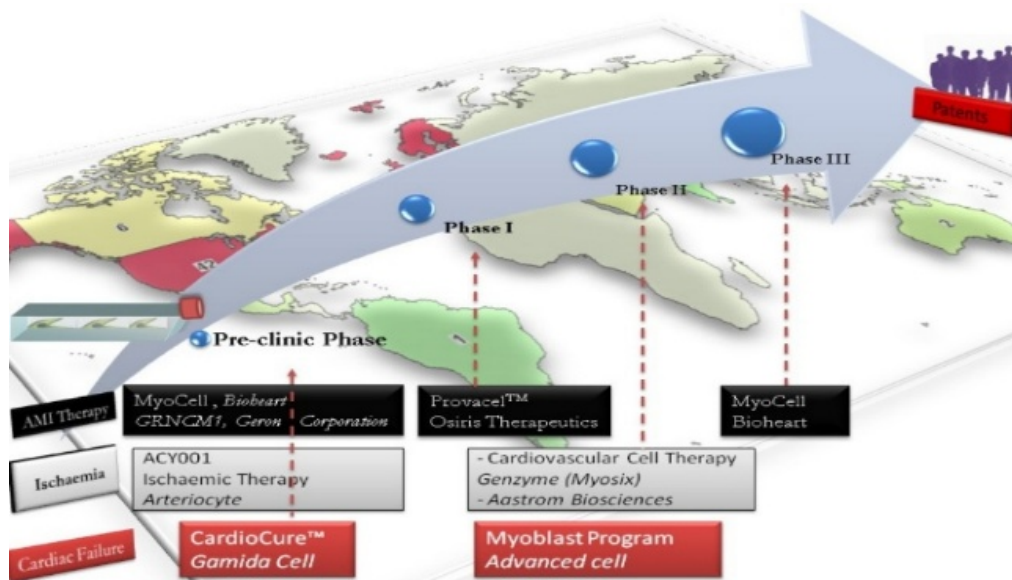


3 Methods used to transdifferentiate MSCs to cardiomyocyte like-cells; (image adapted of Advances In Regenerative Medicine)

Argentine veterinary scientists are studying the possibility of using stem cells as transporters for nanoparticles for certain types of cancer.

*“ Stem cells have the potential to treat a variety of diseases in veterinary patients. However, it's important to note that many more steps may be necessary to put them into practical therapeutic application.”*

Shingo Hatoya (Osaka University – February 2025)



4 Products in development for cell therapy



Beyond therapeutic applications, these techniques could be applied to drug discovery, as they can be generated from patients with genetic diseases.

In addition to their therapeutic applications, these techniques can also be used in the development and discovery of new drugs, as they allow for the generation of cellular models from patients with genetic diseases, allowing for a better study of pathophysiology and the evaluation of potential treatments.

The future looks promising for this branch of medicine that we know as regenerative medicine, but at the same time it demands that we act with the responsibility and seriousness that corresponds, stem cells allow us to do a lot thanks to their lack of the major histocompatibility complex type II, but they impose a limit on us and that is that each species, both human and animal, have their own leukocyte antigens.

This brings us to the same old question: what are we looking for? eternal youth or a quality of life in old age? Personally, I lean toward the latter.

## **References**

Bianco P, Riminucci M, Gronthos S, Robey PG (Bone marrow stromal stem cells: nature, biology, and potential applications. Stem Cells 19:180-192.2001).

DiFiglia M, Sapp E, Chase KO, Davies SW, Bates GP, Vonsattel JP, Aronin N (Aggregation of huntingtin in neuronal intranuclear inclusions and dystrophic neurites in brain. Science 277:1990-1993.1997).

Enzmann GU, Benton RL, Talbott JF, Cao Q, Whittemore SR (Functional considerations of stem cell transplantation therapy for spinal

cord repair. J Neurotrauma 23:479-495.2006).

Glejzer A, Laudet E, Leprince P, Hennuy B, Poulet C, Shakhova O, Sommer L, Rogister B, Wislet-Gendebien S (Wnt1 and BMP2: two factors recruiting multipotent neural crest progenitors isolated from adult bone marrow. Cell Mol Life Sci 68:2101-2114.2011).

Gogel S, Gubernator M, Minger SL (Progress and perspectives: stem cells and neurological diseases. Gene Ther 18:1-6.2011).



Grigoriadis N, Lourbopoulos A, Lagoudaki R, Frischer JM, Polyzoidou E, Touloumi O, Simeonidou C, Deretzi G, Kountouras J, Spandou E, Kotta K, Karkavelas G, Tascos N, Lassmann H (Variable behavior and complications of autologous bone marrow mesenchymal stem cells transplanted in experimental autoimmune encephalomyelitis. *Exp Neurol* 230:78-89.2011).

Assmus, B.; Tonn, T.; Seeger, FH.; Yoon, CH.; Leistner, D.; Klotsche, J.; Schächinger, V.; Seifried, E.; Zeiher, A.M.; & Dimmeler, S. (2010). Red Blood Cell Contamination of the Final Cell Product Impairs the Efficacy of Autologous Bone Marrow Mononuclear Cell Therapy. *Journal of the American College of Cardiology*, Vol. 55, No. 13, ISSN 0735-1097/10/\$36.00, doi:10.1016/j.jacc.2009.10.059

Ay, I.; Lu, J.; Ay, H.; Sorensen, AG. (2009). Vagus nerve stimulation reduces infarct size in rat focal cerebral ischemia. *Neuroscience Letters*, 459, pp. 147–151.

Baba, T.; Kameda, M.; Yasuhara, T.; Morimoto T.; Kondo, A.; Shingo, T.; Tajiri, N.; Wang, F.; Miyoshi, Y.; Borlongan, CV.; Matsumae, M.; Date, I. (2009). Electrical Stimulation of the

Cerebral Cortex Exerts Antiapoptotic, Angiogenic, and Anti-Inflammatory Effects in Ischemic Stroke Rats Through Phosphoinositide 3-Kinase/Akt Signaling Pathway. *Stroke*, 40, pp. e598-e605.

Bliss, TV.; & Collingridge, GL. (1993). A synaptic model of memory: long-term potentiation in the hippocampus. *Nature*, 361, pp. 31-39.

Breschi, GL.; Librizzi, L.; Pastori, C.; Zucca, I.; Mastropietro, M.; Cattalini, A. & Curtis, Md. (2010). Functional and structural correlates of magnetic resonance patterns in a new in vitro model of cerebral ischemia by transient occlusion of the medial cerebral artery, *Neurobiology of Disease*, 39, pp. 181–191.

Carvajal-Vergara, X.; Seville, A.; D'Souza, SL; Ang ,YS; Schaniel, C.; Lee, D.F.; Yang, L.; Kaplan, A.D.; Adler, E.D.; Rozov, R.; Ge, Y.; Cohen, N.; Edelmann, L.J.; Chang, B.; Waghray, A.; Su, J.; Pardo, S.; Lichtenbelt, K.D.; Tartaglia, M.; Gelb, B.D. & Lemischka, I.R. (2010). Patient-specific induced pluripotent stem-cell-derived models of LEOPARD syndrome. *Nature* 465:808–812

Chien, K.; Atsushi, N. & Haruko N. Methods for production of atrial



progenitors and their differentiation into smooth muscle cells and cardiomyocytes. US Patent Application 0003327 (2011).

Chien, KR & Chang, YS Regeneration and survival of cardiac progenitors and cardiomyocytes with a stretch activated transcription factor. WO 2008/054819 A2 (2008).

Choi, Y.S.; Dusting, G.J.; Stubbs, S.; Arunothayaraj, S.; Han, XL; Collas, P.; Morrison, W.A. & Dilley, R.J. (2010). Differentiation of human adiposederived stem cells into beating cardiomyocytes. J Cell Mol Med 14:878-89.

Cowan, C.A.; Atienza, J.; Melton, D.A. & Eggan, K. (2005). Nuclear reprogramming of somatic cells after fusion with human embryonic stem cells. Science 309:1369-1373

Dawn, B. & Bolli, R. (2005). Adult bone marrow-derived cells: regenerative potential, plasticity, and

tissue commitment. Basic Res Cardiol 100:494–503.

Dimos, JT; Rodolfa, KT; Niakan, K.K.; Weisenthal, L.M.; Mitsumoto, H.; Chung, W.; Croft, G.F.; Saphier, G.; Leibel, R.; Goland, R.; Wichterle, H.; Henderson, C.E. & Eggan, K.(2008). Induced pluripotent stem cells generated from patients with ALS can be differentiated into motor neurons. Science 321:1218–1221.

Efe, JA; Hilcove, S.; Kim, J.; Zhou, H.; Ouyang, K.; Wang, G.; Chen, J. & Ding, S. (2011). Conversion of mouse fibroblasts into cardiomyocytes using a direct reprogramming strategy. Nat Cell Biol 13:215-22.

Fernandez-Aviles, F.; San Roman, JA; Garcia-Frade, J.; Fernandez, ME; Peñarrubia, MJ; de la Fuente, L.; Gómez-Bueno, M.; Cantalapiedra, A., Fernández, J.; Gutierrez, O.; Sánchez, PL; Hernandez, C.; Sanz, R.; García-Sancho, J. & Sánchez A. (2004).



**INTEGRAVET**  
Orthobiologic | Centro de Fisiatría &  
Lab | Medicina Regenerativa



Grupo Andes – Investigación y Desarrollo en Medicina Regenerativa Veterinaria (C) Copyright (2025) Todos los Derechos Reservados



Grupo Andes – Investigación y Desarrollo en Medicina Regenerativa  
Veterinaria (C) Copyright (2025) Todos los Derechos Reservados